



Cesarean section for breech presentation

Jonathan H. Waters, M.D.

- 26 y.o. G1P0 presented to triage in labor at 38 weeks.
- Patient was a known breech with a failed version 5 days before presentation.
- PMH negative
- PSH negative
- Social Hx-no alcohol, tobacco or drug use. Lives with husband.
- Medications-PNV

Version Vital signs Temp 37.2°C, BP 122/73, HR 81, RR 22,
O2 Sat 99%

Admission Vital signs Temp 37.0°C, BP 135/84, HR 68, RR
16, O2 Sat 99%

Would anything about this patient's presentation be suggestive of pre-eclampsia?

- Yes
- No
- Maybe
- I don't know

Pre-eclampsia is diagnosed when a pregnant woman develops:

- Blood pressure ≥ 140 mm Hg systolic or ≥ 90 mm Hg diastolic on two separate readings taken at least four to six hours apart after 20 weeks gestation in an individual with previously normal blood pressure.
- In a woman with essential hypertension beginning before 20 weeks gestational age, the diagnostic criteria are: an increase in systolic blood pressure (SBP) of ≥ 30 mmHg or an increase in diastolic blood pressure (DBP) of ≥ 15 mmHg.
- Proteinuria ≥ 0.3 grams (300 mg) or more of protein in a 24-hour urine sample or a SPOT urinary protein to creatinine ratio ≥ 0.3 or a urine dipstick reading of 1+ or greater (dipstick reading should only be used if other quantitative methods are not available).

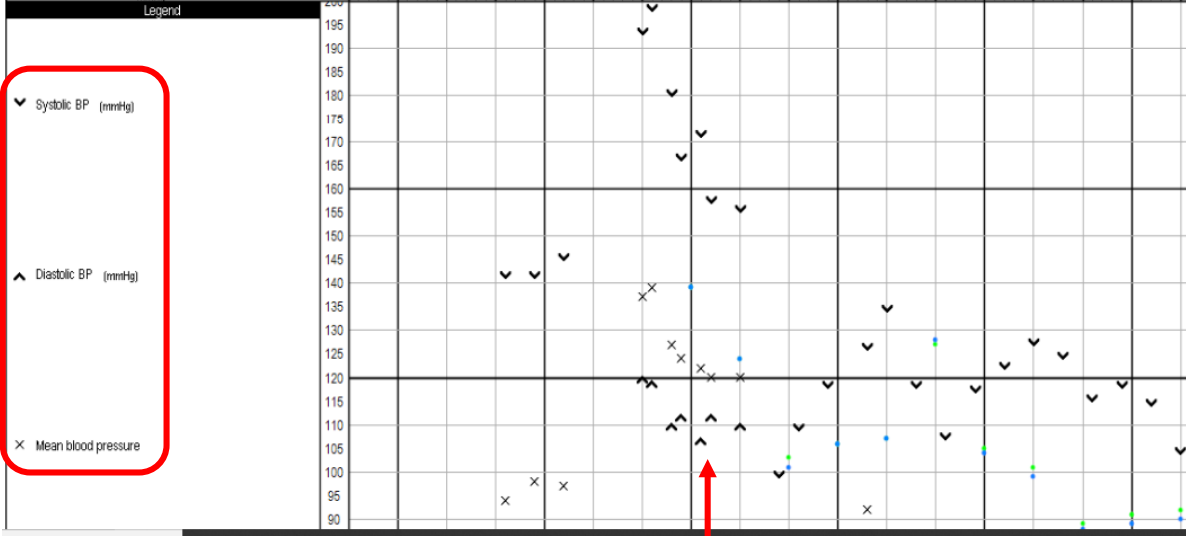


← Time

Name	Total	7:45	8:00	8:15	8:30	8:45
Medications						
=LACTATED RINGERS IV	1200 mL					
=CEFAZOLIN IV	2 gm		2 gm			
=EPHEDRINE IV	15 mg		15 mg			
=PHENYLEPHRINE IV	400 mcg					
=OXYTOCIN 30 UNITS/500 ML IV	17.4 Unit(e)					
=BUPIV 0.75%/DEX 0.25% SPINAL Intrathecal	1.6 mL		1.6 mL			
=MORPHINE PRES FREE 0.5MG/ML Intrathecal	0.2 mg		0.2 mg			
=GLYCOPYRROLATE IV	0.2 mg		0.2 mg			
=ESMOLOL IV	40 mg		10 mg	10 mg	10 mg	10 mg
=MAGNESIUM SULFATE IV	7.2 gm					7.2 gm
=MIDAZOLAM IV	2 mg				2 mg	
=PROPOFOL IV	50 mg				50 mg	
=ONDANSETRON IV	8 mg					8 mg
=FENTANYL IV	50 mcg					50 mcg

Gases						
Oxygen Flow Rate L/min		4	4			
Oxygen % (FiO2)		100	100	100	100	97
Nitrous Oxide ET %		0	0	0	0	0

Monitors						
EKG Rhythm		SR	SR	ST	ST	SR
Forced Air Warmer		Off	Off	Off	Off	Off
Temp DegC					36	
Mode of Ventilation		SV	SV	SV	AV	SV
SpO2 %		98.9	96.2	98.4	100	100
ETCO2 mmHg		0	0	0	49	40
Respiratory Rate		0	0	0	7	21
Ambient Pressure AGM mmHg		733	733	733	733	733



Legend

Common Vasopressors

- Phenylephrine-selective α_1 -adrenergic receptor agonist. Phenylephrine can also cause a decrease in heart rate through reflex bradycardia.
- Ephedrine-indirect acting α_1 and β -adrenergic receptor agonist

0807 Patient started complaining of a severe headache-the worst that she had ever experienced. Two minutes later she started complaining of seeing something in the left corner of her eye. Shortly thereafter, she had a tonic-clonic seizure which was controlled with 2 mg Versed and 50 mg propofol.

NEURO

MS: Alert and oriented to person, place, date and situation. Speech without dysarthria. Language fluent and appropriate, language intact. Cognition and memory grossly intact. Attention intact. Naming and repetition intact. Abstractions intact. Fund of knowledge and vocabulary grossly.

CN: VF grossly full to confrontation. PERRL. EOMI. Facial sensation intact to LT. Facial muscles full and symmetric. Hearing intact to finger rub bilaterally. Uvula midline with symmetric palatal elevation. SCMs and shoulder shrug normal. Tongue midline.

MOTOR: Normal bulk and tone. No adventitious movements or bradykinesia. No pronator drift.

	<u>Deltoid</u>	<u>Biceps</u>	<u>Triceps</u>	<u>Wr ext</u>	<u>Wr flex</u>	<u>Handgrip</u>
<u>Left</u>	5/5	5/5	5/5	5/5	5/5	5/5
<u>Right</u>	5/5	5/5	5/5	5/5	5/5	5/5
	<u>Iliopsoas</u>	<u>Knee flex</u>	<u>Knee ext</u>	<u>Tib Ant</u>	<u>Gastroc</u>	
<u>Left</u>	5/5	5/5	5/5	5/5	5/5	
<u>Right</u>	5/5	5/5	5/5	5/5	5/5	

REFLEXES: 3+ at biceps, triceps, brachioradialis, 3+ patella, and 3+ achilles bilaterally. Brisker on R than L. Withdrawal to plantar stimulation on L, mute on R.

SENSORY: Normal to light touch, vibration, pain, temperature in upper and lower extremities. Position sense intact in upper and lower extremities. Romberg sign is absent.

COORDINATION: no dysmetria or ataxia on finger-to-nose. RAM symmetric bilaterally without slowing.

GAIT: Deferred due to clinical state

What is your preliminary diagnosis?

- Eclampsia
- Subarachnoid hemorrhage
- Thrombotic stroke
- Unrecognized glioma
- Other

CT of the brain

Impression:

Perfusion imaging shows striking increased mean transit time and decreased relative cerebral blood flow throughout the visual posterior circulation in the occipital lobes. These findings suggest diffuse vertebrobasilar ischemia without evidence of infarct. There is also some subtle irregular nodularity of the distal right PCA, an abnormal finding in a patient of this age. Given the patient's post-partum history and seizure, the findings raise the possibility of posterior reversible encephalopathy syndrome (PRES), although CT perfusion imaging of PRES is not well described in the medical literature, consisting only of a few case reports. Further evaluation with MR brain and intracranial MR angiogram is recommended.

No acute intracranial hemorrhage, herniation, or hydrocephalus.

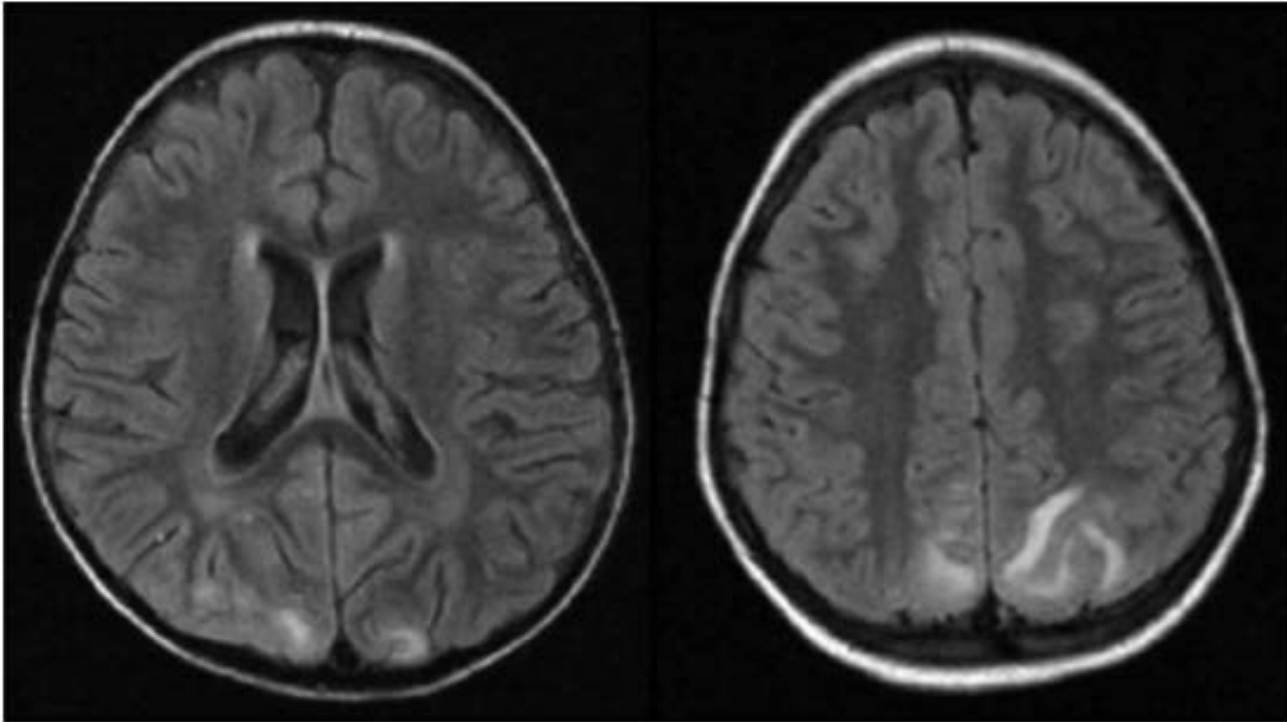


Figure 1. Brain magnetic resonance imaging (FLAIR) showing an increase of signal in both parieto-occipital lobes.

Objective

EEG Description: This urgent/portable 22 channel digital EEG recording had a total time of 44 minutes.

Background: There was well developed 9-10 Hz, symmetric posterior dominant rhythm, which attenuates with eye opening. The anterior to posterior gradient was present. The predominant background EEG frequency was 8-9 HZ. The predominant feature of the recording was overlying intermittent 1 Hz polymorphic delta activity over bilateral posterior quadrants, especially left. Rarely slowing was generalized 1-2Hz lasting 1-2 seconds. Spontaneous variability of the EEG background was present.

Activation:

The patient did answer questions, and follow commands. There was no additional abnormal activation during photic stimulation. Hyperventilation was unable to be performed. There was no well developed photic driving.

Sleep: The patient was drowsy, but did not enter deeper levels of sleep.

Epileptiform discharges: There were rare 70-100 μ V sharp waves over left and right temporal parietal occipital regions .

Seizures: None.

Additional channels: The EKG monitor was unremarkable.

Test Interpretation

EEG interpretation: This is an abnormal urgent EEG recording due to the presence of rare left > right sharp waves and intermittent delta slowing in the temporal-parietal-occipital regions bilaterally which is suggestive of a tendency for focal seizures and focal dysfunction. No seizure discharges were present during this recording.

POD #1 MRI with and without contrast

IMPRESSION:

MRI brain:

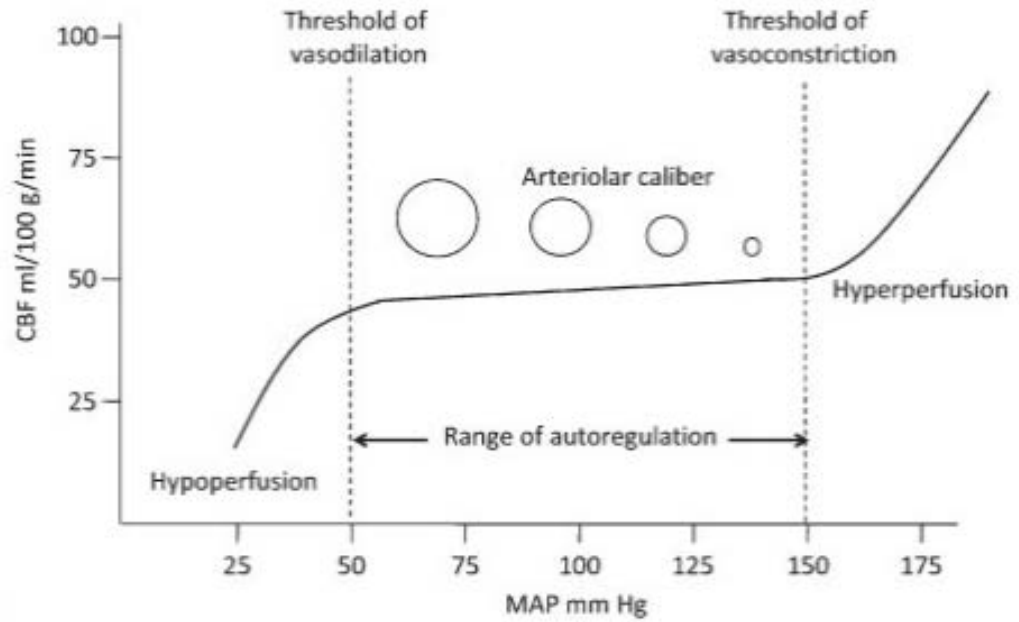
No acute intracranial process.

MRA brain:

Despite motion, no abrupt vessel occlusion, suggestion of flow-limiting stenosis or large intracranial aneurysm.

Posterior Reversible Encephalopathy Syndrome (PRES)

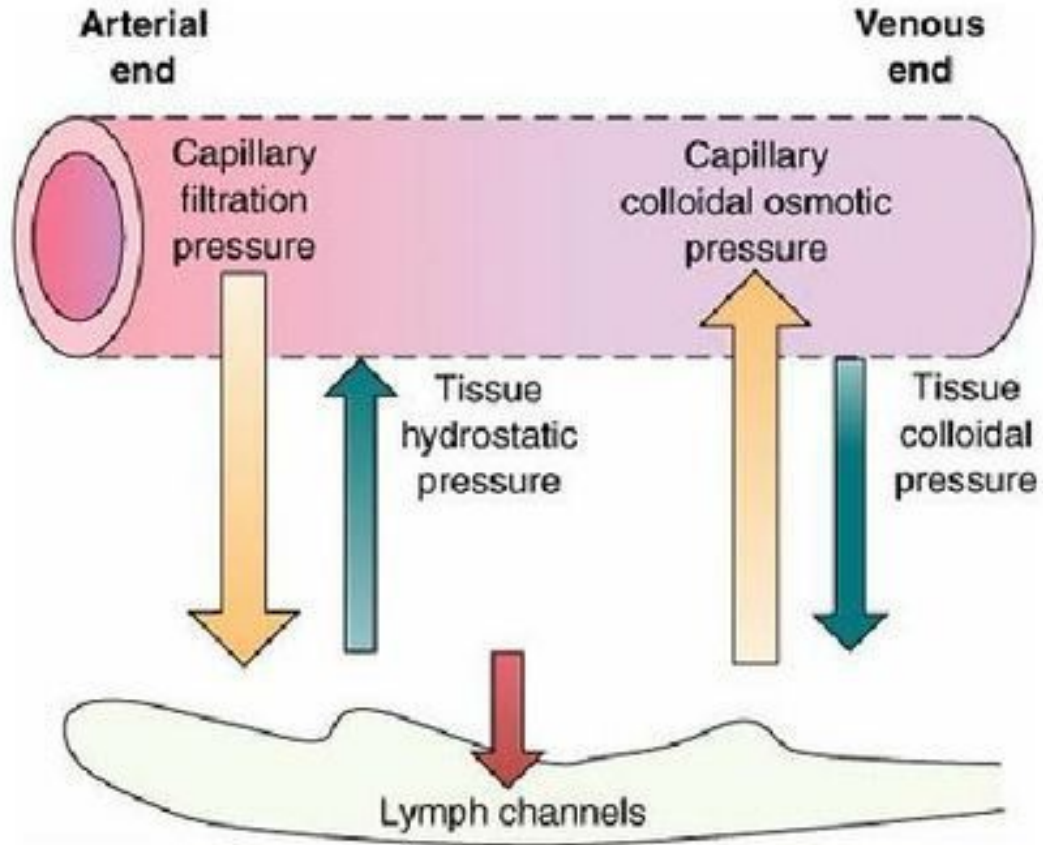
- Also known as:
 - Hypertensive encephalopathy (THE)
 - Reversible posterior leukoencephalopathy syndrome (RPLS)
 - Reversible Posterior Cerebral Edema Syndrome



A

Feske SK. Semin Neurol 2011;31:202

Starling Forces



Posterior Reversible Encephalopathy Syndrome (PRES)

- Autoregulatory breakdown
- Unimpeded rise in cerebral perfusion pressure
- Extravasation of plasma
- Cerebral edema

Hospital Course

- Discharged home on POD#3
- Returned in October, 2017 for repeat cesarean section which was uneventful.